

# Metastatic tumor of the left atrium (RCD code: VI-20)

**Zbigniew Gąsior\*<sup>1</sup>, Katarzyna Mizia-Stec<sup>2</sup>, Maria Kasztelan-Masłowska<sup>3</sup>,  
Mariusz Skowerski<sup>1</sup>, Krzysztof Januszewski<sup>4</sup>, Piotr Pysz<sup>1</sup>**

<sup>1</sup> Department of Cardiology, Department of Cardiology, School of Health Sciences in Katowice, Medical University of Silesia; <sup>2</sup> 1st Department of Cardiology, School of Medicine in Katowice, Medical University of Silesia; <sup>3</sup> 2nd Department of Cardiology, Upper Silesian Medical Centre, Katowice; <sup>4</sup> Upper Silesian Medical Centre, Katowice

## Abstract

We present a case report concerning a 59-year-old patient diagnosed with intracardiac tumor two years after removal of soft tissue sarcoma of the right lower extremity. JRCd 2016; 2 (6): 189–191

**Key words:** hemangiopericytoma, metastases, echocardiography, cardiac surgery

## Background

Cardiac tumors may either be primary or, more frequently, metastatic in nature. During autopsy they are found in 1–20% of patients with oncologic disorders, mostly carcinoma of lung and breast, melanoma and leukemia [1,2]. Metastatic cardiac tumors usually occupy heart in result of expansion through circulatory system. Direct infiltration only takes place in case of lymphocytoma and lung cancer [1–3]. Symptoms and complications are mostly dependent on tumor's location – pericardial, myocardial or intracardiac whereas histologic features are of less significance. We report a case of a patient who had a popliteal tumor removed and presented with lungs metastases and left atrial (LA) tumor.

## Case description

59-year-old male was diagnosed with hemangiopericytoma two years earlier after excision and histological examination of a right popliteal fossa tumor. Since metastatic lesions in the lungs were also found chemo- and radiotherapy were administered. Next surgical excision of the metastases was performed and chemotherapy continued. One year later laser excision of another metastatic lesion in the right lung was performed. Similar procedure was being planned for the left lung metastasis when a left atrial (LA) tumor was visualized in a chest computed tomography CT scan (Figure 1). Consequently, the patient was admitted to Cardiology Department.

On admission the patient was asymptomatic with blood pressure of 120/80 mmHg and heart rate of 70 bpm. First heart sound was slightly accentuated and a 2/6 systolic murmur could be auscultated in the Erb's point. Respiratory sounds were normal and there were no signs of decompensated heart failure (HF). Peripheral pulse was symmetrically palpable. ECG was normal.

Transthoracic echocardiography showed presence of an abnormal structure in the LA. It measured 28×32 mm with an area of about 9 cm<sup>2</sup> and displayed a smooth contour and irregular echogenicity. It was attached by a wide stalk to the LA wall but concurrently fairly mobile and entering the left ventricle (LV) across the mitral valve (MV) during diastole (Figure 2). LA size was normal (dimension of 38 mm, area of 16 cm<sup>2</sup>) and so were the anatomy and function of the LV. Mitral inflow velocity was only slightly accelerated and there was mild mitral regurgitation. Moderate tricuspid regurgitation was also found with calculated right ventricular (RV) systolic pressure of 42 mmHg. Other heart valves were normal. There were no stenotic lesions in coronary angiogram (CA).

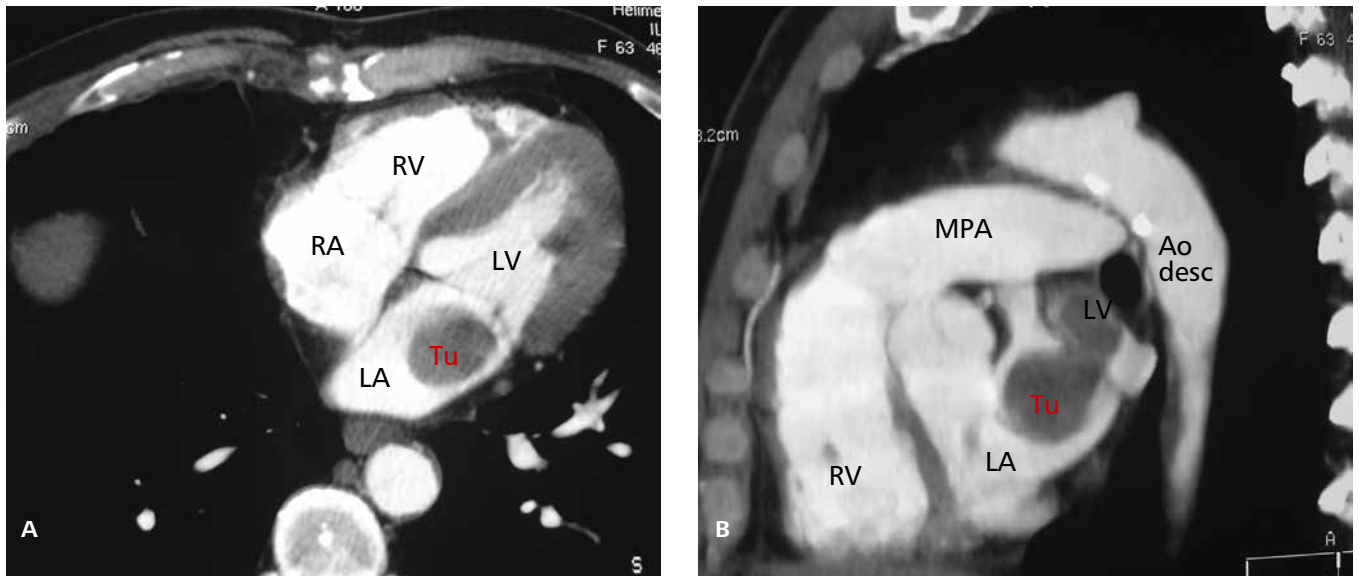
Laboratory findings did not reveal any abnormalities with white blood count and haemoglobin concentration within normal limits.

The patient was transferred to Cardiac Surgery Department. White-grey brittle tumor of about 4 cm in diameter was removed from LA. Histological diagnosis was non-epithelial, necrotizing malignant neoplasm (G2) – malignant hemangiopericytoma (Figure 3).

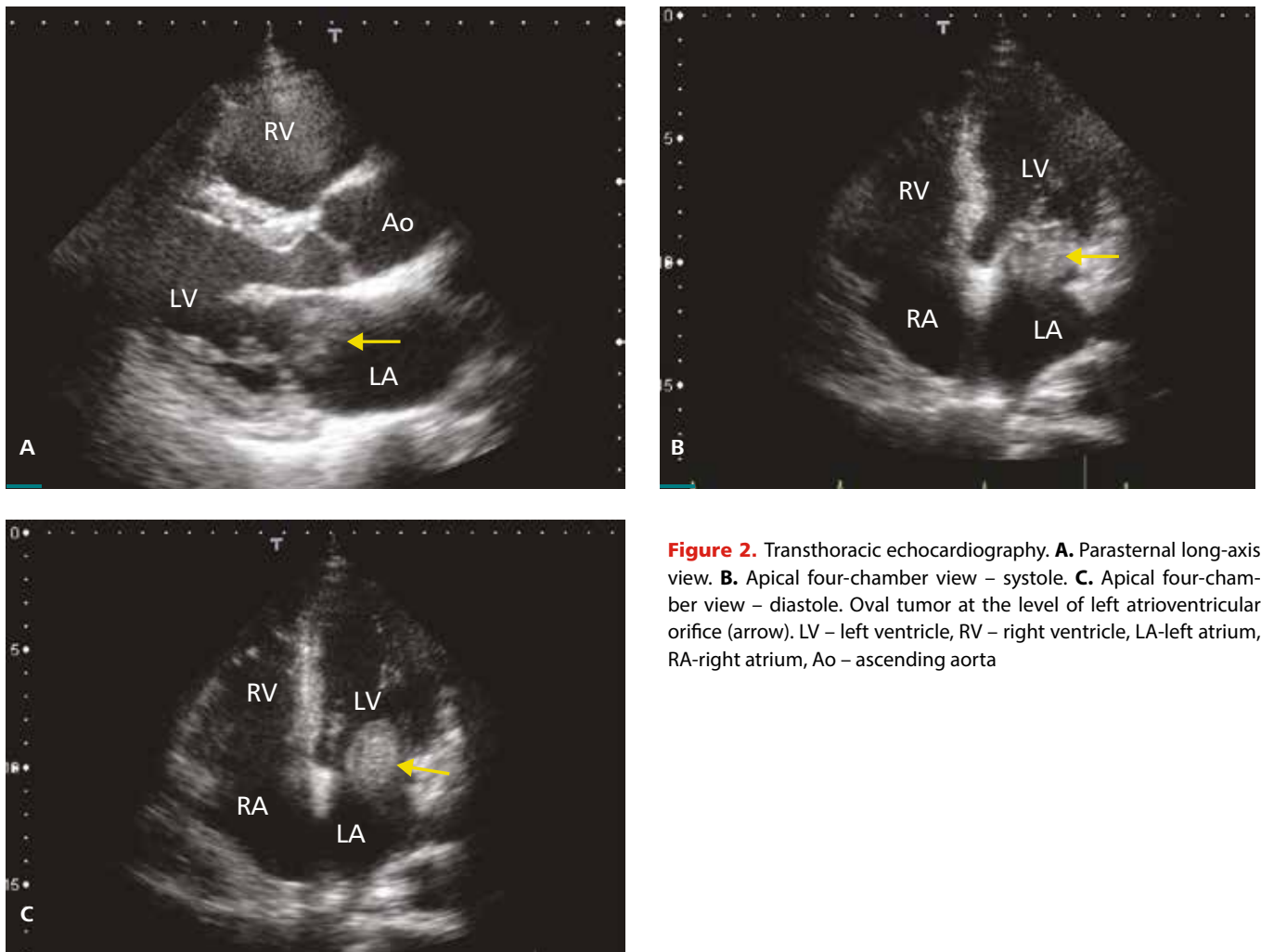
Conflict of interest: none declared. Submitted: November 13, 2015. Accepted: March 5, 2016.

\* Corresponding author: Department of Cardiology, School of Medicine in Katowice, Medical University of Silesia, ul. Ziolowa 47, 40-635 Katowice-Ochojec, Poland; tel./fax 032 2 527 407; e-mail: zgasior@sum.edu.pl

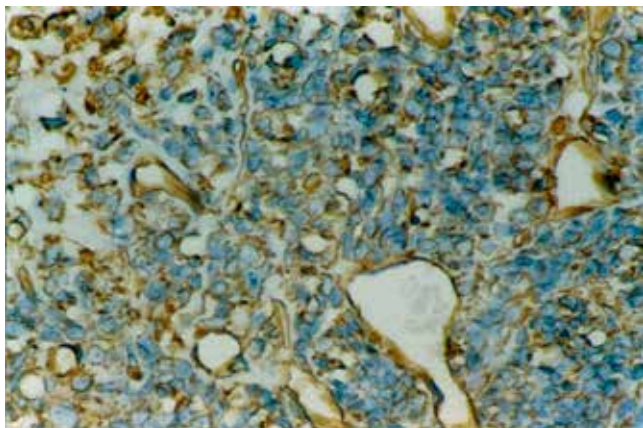
Copyright © 2015 Journal of Rare Cardiovascular Diseases; Fundacja Dla Serca w Krakowie



**Figure 1.** Computed tomography. The tumor (Tu) is visualized as unopacified area in the left atrium. A. Horizontal plane. B. Sagittal plane. LV – left ventricle, RV – right ventricle, LA-left atrium, RA-right atrium, Ao desc – descending aorta, MPA- main pulmonary artery



**Figure 2.** Transthoracic echocardiography. **A.** Parasternal long-axis view. **B.** Apical four-chamber view – systole. **C.** Apical four-chamber view – diastole. Oval tumor at the level of left atrioventricular orifice (arrow). LV – left ventricle, RV – right ventricle, LA-left atrium, RA-right atrium, Ao – ascending aorta



**Figure 3.** Histological examination of the left atrial tumor revealed hemangiopericytoma malignum

## Discussion

We presented a case of a patient with a 2-year history of disseminated neoplastic disease. The primary lesion was removed and chemo- along with radiotherapy were applied. Nevertheless, lungs metastases developed and were treated both surgically and with laser excision. The finding in LA warranted rapid ultrasound diagnostics and cardiac surgery.

What captures the attention is the expansive character of the process. Even though the patient was undergoing repetitive chest CT scans the intervals between them proved long enough for a large tumor to grow.

Somehow surprisingly our patient remained asymptomatic. Tumors in this location are known to mimic MV disease. In case of dynamic LV outflow tract obstruction the symptoms may be posture-dependent and occur suddenly [1]. Restriction of mitral inflow can both result in LV filling impediment and peripheral embolism in case of which meticulous clinical and echocardiographic assessment are mandatory.

Tumor removed from the right popliteal fossa was histologically identified as hemangiopericytoma, a rare type of vessel tissue sarcoma. The lesion removed from LA, also a hemangiopericytoma, was most probably of metastatic origin and secondary to pulmonary metastases. However, the possibility of primary growth of this kind of sarcoma within cardiac chambers should be taken into account as well.

Primary malignant lesions constitute 25% of all cardiac tumors and in adults nearly all of them are sarcomas. Those originating from vessel tissue are found in up to 3% of cases [1,2,3]. They typically occur in male patients between the age of 30 and 60 and most frequently occupy right atrium (RA), LA, RV, LV and interventricular septum, respectively. Their growth, in an infiltrating or polypoid form, is rapid and commonly accompanied by pulmonary, mediastinal and spinal metastases with average survival of 2 years. Since RA and RV are typical locations right HF symptoms are fairly often [1,5]. The majority of so far reported primary cardiac hemangiopericytoma cases were benign RA tumors with right HF symptoms [6,7]. The left heart was sporadically involved [8] and malignant

character was also rare [9]. We did not find any previous reports on cardiac location of hemangiopericytoma metastases.

Described site of the lesion necessitates differentiation with myxoma, the most frequent LA tumor. In the hereby presented case the clinical and histological data were diagnostic. At the same time, one should acknowledge that the sole echocardiographic appearance was a straightforward indication for urgent cardiac surgery even despite previous histological findings.

Our patient was exposed to a number of risk factors for myocardial ischemia (radiotherapy, potential neoplastic embolism) but did not report angina symptoms. As CA was normal the extent of cardiac surgery could be limited.

## References

1. Colucci WS, Scoen FJ. Primary tumors of the heart. [in:] Braunwald E, Zipes DP, Libby P (Eds.). Heart disease: a textbook of cardiovascular medicine. WB Saunders, Philadelphia 2001; 1807–1822.
2. Stone RM, Bridges KR, Libby P. Hematological-oncological disorders and cardiovascular disease. [in:] Braunwald E, Zipes DP, Libby P (Eds.). Heart disease: a textbook of cardiovascular medicine. WB Saunders, Philadelphia 2001; 223–224.
3. Komar M, La Canna G, Gancarczyk U, et al. Update on Cardiac Tumors – review. JRCO 2014; 1 (8): 5–10.
4. Abraham KP, Reddy V, Gattuso P. Neoplasms metastatic to the heart: review of 3314 consecutive autopsies. Am J Cardiovasc Pathol 1990; 3(3):195–198.
5. Burke AP, Cowan D, Virmani R. Primary sarcomas of the heart. Cancer 1992;69(2):387–395.
6. Butany J, Yu W. Cardiac angiosarcoma: two cases and a review of the literature. Can J Cardiol 2000;16(2):197–205.
7. Orlandi A, Ferlosio A, Ciucci A, et al. Unusual cardiac tumour with perivascular myoid differentiation: a case report. J Clin Pathol 2004;57(12):1338–1340.
8. Dennig K, Lehmann G, Richter T. An angiosarcoma in the left atrium. N Engl J Med. 2000;342(6): 443–444.
9. Okada Y, Mori H, Yoshii Y, et al. Case of primary malignant hemangiopericytoma of the heart expressing basement membrane-degradable enzymes. Pathol Int. 2002; 52(8): 544–550.