

Macitentan therapy for bosentan hepatic intolerance in Eisenmenger's syndrome patient (RCD code: II-1A.4d)

Marta Nowakowska*, Agnieszka Mossakowska, Łukasz Chrzanowski, Michał Simiera, Jarosław Damian Kasprzak

Medical University of Lodz, Department of Cardiology, Lodz, Poland

Abstract

Pulmonary arterial hypertension associated with congenital heart disease is included in clinical group 1 pulmonary arterial hypertension. Eisenmenger's syndrome develops over time as a result of large intra- and extra-cardiac arterial and venous blood communication. The pulmonary vascular resistance (PVR) increases and thus the systemic-to-pulmonary blood flow reverses direction, producing a pulmonary-to-systemic shunt (Eisenmenger's syndrome). Bosentan, an oral endothelin receptor antagonist A and B, is recommended in monotherapy and drug combination therapy in this group of patients. Liver toxic reactions occur in about 10% of treated patients but severe hepatotoxicity is rare. We present a clinical case of a patient with Eisenmenger's syndrome due to large ventricular septal defect. The patient was for many years successfully treated with bosentan and subsequently developed drug-induced hepatitis. JRC D 2016; 2 (8): 259–262

Key words: congenital heart disease, pulmonary hypertension, hepatotoxicity, endothelin receptor

Case presentation

We present a case of a patient with pulmonary arterial hypertension (PAH) associated with a congenital heart defect. We describe the patient treated with bosentan who unexpectedly developed drug-induced hepatic injury several years after treatment. Bosentan was discontinued and the patient started macitentan treatment as needed to maintain a therapeutic response.

Reported patient is a 67-years-old Caucasian female with Eisenmenger's syndrome due to large ventricular septal defect (VSD). She had a history of cyanosis and presented a lower exercise capacity compared to healthy peers since early childhood. In 2003, she had her first cardiac assessment and was hospitalized at the Department of Cardiac Surgery to evaluate an undefined congenital heart defect. A transthoracic echocardiogram showed a ventricular septal defect (VSD) estimated at 1.3 cm diameter with bidirectional shunt, moderate tricuspid regurgitation and severe pulmonary hypertension with estimated systolic pulmonary pressure (sPAP) of 128 mm Hg, right atrial and ventricular enlargement with right ventricular hypertrophy and normal left ventricular ejection fraction (EF) of

69%. A ventilation/perfusion (V/Q) lung scan demonstrated normal results. Coronary angiography showed no significant coronary stenosis. Based on the clinical presentation the patient was not considered for cardiac surgery and thus for many years she remained under ambulatory follow-up receiving diltiazem treatment. During this period, she experienced two episodes of hemoptysis (2003, 2008). In 2008 the patient was found to be infected with tuberculosis and underwent standard antibiotic therapy. In 2010 right heart catheterization confirmed severe pulmonary hypertension: mean pulmonary artery pressure (mPAP) was 79 mm Hg with high pulmonary vascular resistance (PVR) of 17.7 Wood units, cardiac output (CO) was 3.79 l/min, cardiac index (CI) was 2.69 l/min/m². Afterwards, the patient was referred to the pulmonary hypertension center and enrolled in a nationally coordinated treatment program. Bosentan therapy was initiated according to the protocol of group 1 PAH associated with a congenital heart disease (Eisenmenger's syndrome due to VSD). Clinical examination showed respiratory rate of 22 breaths per minute, blood pressure of 140/80 mm Hg and heart rate of 70 beats per minute. The patient was in good condition, without dyspnoea at rest, but her exercise capacity was much lower

Conflict of interest: none declared. Submitted: April 28, 2016. Accepted: August 16, 2016.

* Corresponding author: Medical University of Lodz, Department of Cardiology, Bieganski Hospital, Kniaziewiczza 1/5 str., 91-347 Lodz, Poland; tel. +48 42 251 62 16; e-mail: now-mart@o2.pl

Copyright © 2016 Journal of Rare Cardiovascular Diseases; Fundacja Dla Serca w Krakowie

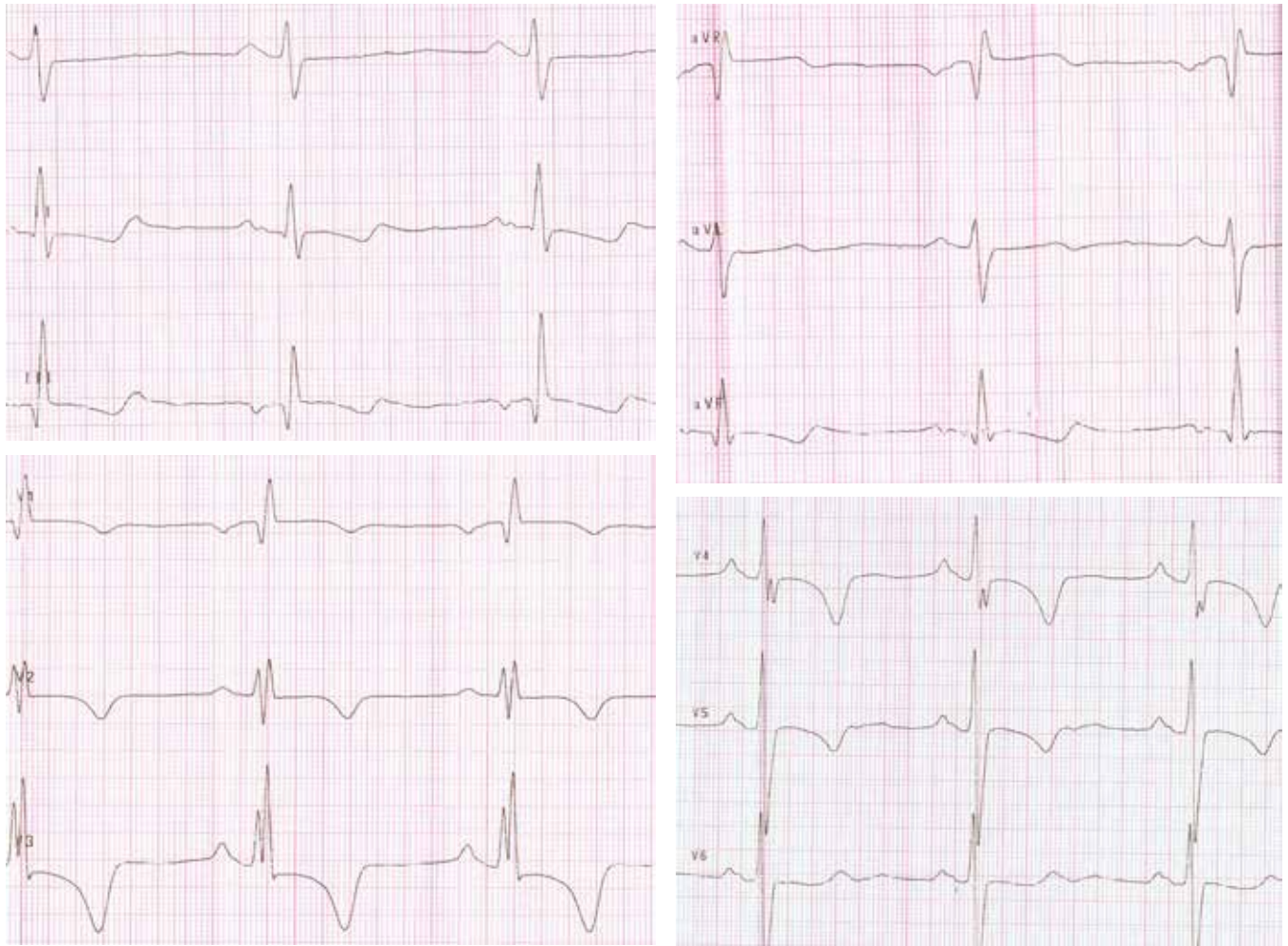


Figure 1. Electrocardiogram registered at the first hospitalization

than her peers. She denied hemoptysis (since last episode in 2008) and syncope. Electrocardiogram (ECG) showed: sinus rhythm 70/min, right axis deviation, right ventricular hypertrophy, pathological Q waves in III, aVF leads; downsloping ST segment depression with T wave inversion in II, aVF, V3-V5 leads (upper limit 2 mm in V3 lead), T wave inversion in III lead (Figure 1). Arterial blood gas test showed arterial oxygen pressure (pO₂) below normal values with normal arterial carbon dioxide pressure (pCO₂). Other blood tests revealed oxygen saturation of 90% at room air, white cell count of $8.5 \times 10^9/l$ (normal range: $4-10 \times 10^9/l$), red cell count – $5.16 \times 10^6/l$ (normal range: $4.2-5.4 \times 10^6/l$), haemoglobin – 15.9 mg/dl (normal range: 12–16 mg/dl), haematocrit – 47.5% (normal range: 37–50%), platelet count – $205 \times 10^3/l$ (normal range: $150-400 \times 10^3/l$), alanine transaminase (ALT) 15 U/I (normal range: 0–31 U/I), aspartate transaminase (AST) 20 U/I (normal range: 0–32 U/I), bilirubin 0.46 mg/dl (normal range: 0.2–1.0) and N-terminal prohormone of brain natriuretic peptide (NT-proBNP) of 280 pg/ml (normal range: 0–125 pg/ml). The distance of 380 meters in the 6-minute walking test (6 MWT) was achieved. The patient presented was in functional class III, according to World Health Organisation (WHO) classification. Over many years of bosentan-based treatment at full dose of 125 mg

BID, the patient remained clinically stable, with normal biochemical parameters. Figure 2 shows a transthoracic echocardiogram, which was registered during the second year of treatment.

Her 6-minute walking distance ranged between 400–450 m and NT-proBNP value between 386–789 pg/ml. After 5 years of uninterrupted treatment there was a marked asymptomatic increase of transaminases. Hepatologic consultation excluded other causes of hepatopathy and hence an adjunctive liver function treatment with essential phospholipid capsules formulation (Essentiale forte) was initiated, but it was unsuccessful. In June 2015, the transaminases exceeded 5-fold ULN levels (ALT 102 U/I, AST 84 U/I). Thus, bosentan toxicity was also considered a possible etiology. Initially we did not modify treatment but rechecked liver markers. The patient remained asymptomatic and clinically stable in WHO functional class II, 6 MWT was 420 m and NT-proBNP 415 pg/ml. Until August 2015 the transaminases had remained stable, but in September they increased further: ALT up to 170 U/I and AST to 172 U/I. The patient denied any new symptoms; 6 MWT was 450 m, but NT-proBNP also increased up to 1993 pg/ml. The dose of bosentan was reduced to 62.5 mg BID. A month later the patient's blood tests showed decreasing levels of ALT 140 U/I and AST 139 U/I while NT-proBNP stayed on a high level of 1700 pg/ml with 430 m

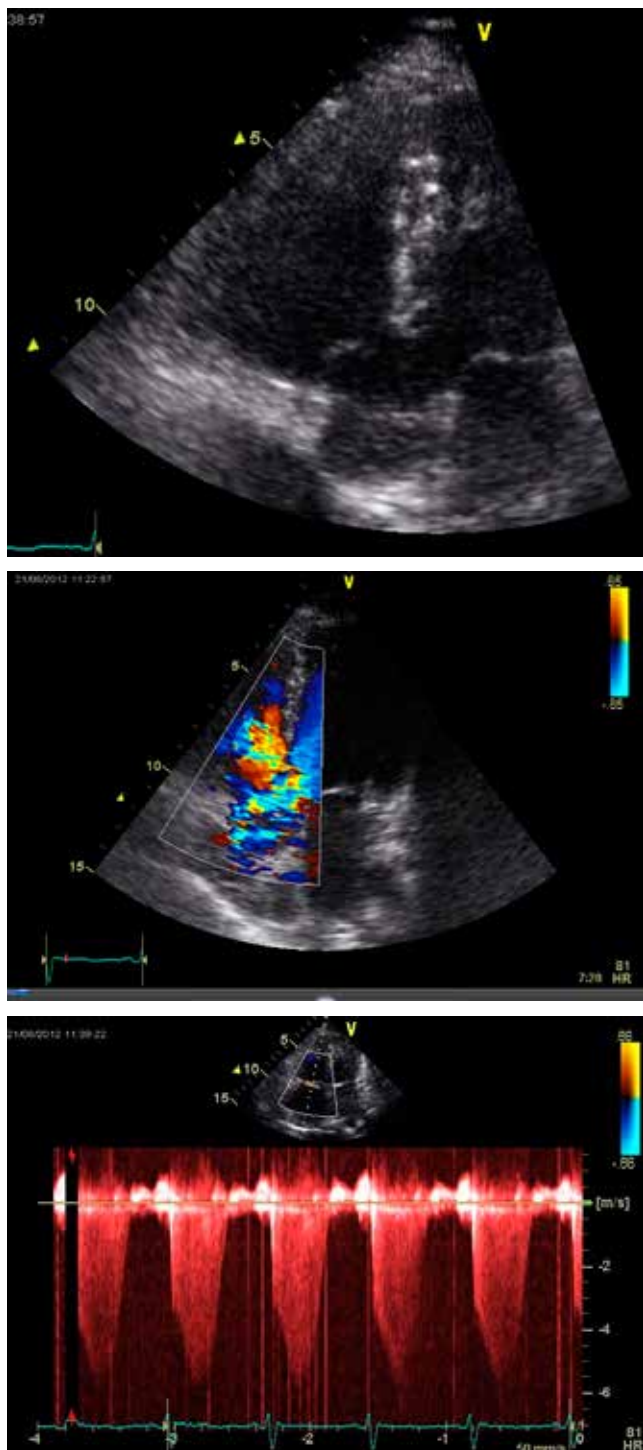


Figure 2. Transthoracic echocardiogram during treatment showed a ventricular septal defect (A), moderate tricuspid regurgitation (B) and severe pulmonary hypertension (C)

6MWT. We subsequently decided to withdraw bosentan and initiate sildenafil instead. After that in November 2015 transaminase levels normalized (ALT 37 U/I; AST 42 U/I), but the patient reported declining functional capacity. 6MWT walking distance was only 390 meters and the NT-proBNP was extremely elevated (3795 pg/ml). We attempted bosentan rechallenge, but transaminases began to increase again (ALT 107 U/I; AST 137 U/I). We also

observed rise in bilirubin level especially in conjugated fraction up to 0,39 mg% and unconjugated to 1,2 mg% but without jaundice. Other blood tests revealed high levels of lactate dehydrogenase (LDH), serum gamma-glutamyl transpeptidase (GGTP), alkaline phosphatase (ALP), but normal level of protein albumin and coagulation parameters.

In December 2015 bosentan was withdrawn and macitentan treatment was initiated. The patient currently receives dual combination specific therapy of sildenafil (20mg TID) and macitentan (10 mg QD) which is well-tolerated. Since then, liver function tests have remained normal (ALT 14 U/I; AST 22 U/I), NT-proBNP decreased to 638 pg/ml and the patient reported improved tolerance of physical capacity with 6MWT distance of 465 m. Additionally other parameters such as level of bilirubin, LDH, GGTP and ALP have normalized. Figure 3 shows changes in biochemical parameters during the treatment.

Discussion

Bosentan, an oral endothelin A and B receptor antagonist, offers a significant benefit in treatment of patients with PAH. The receptor blockade inhibits the binding of endothelin-1 and thus its vasoconstrictor and mitogenic effects on the endothelium of lung vessels, which reduces the pulmonary vascular resistance and the pressure in the pulmonary artery [1,2]. The treatment with bosentan significantly affects the improvement in functional class, physical capacity, hemodynamic parameters, time to clinical worsening in patients with PAH associated with connective tissue disease and Eisenmenger's syndrome [1,3,4,5]. It has been shown that this treatment is associated with an increased risk of liver damage. Elevations of liver transaminases occur in approximately 10% per year and is dose-dependent and reversible after dose reduction or discontinuation of the drug. Due to hepatotoxicity risk, liver function should be regularly checked by transaminases level compared with pretreatment baseline. Increase in activity of liver aminotransferases imposes specific management changes and thus monthly monitoring of liver function test (LFT) is recommended throughout bosentan treatment period. Whenever ALT rises between 3 to 5 times ULN, the dose of bosentan should be reduced or interrupted. Therapy may be continued or reintroduced if transaminases return to pre-treatment values. In case of aminotransferase levels between 5 to 8 times ULN withdrawal of therapy is recommended and if LFTs return to pre-treatment values reintroduction of treatment may be considered with careful monitoring of LFT. Permanent discontinuation of the therapy is mandatory if aminotransferase levels are greater than 8 times ULN [6]. In European post-marketing surveillance of bosentan in PAH trial, 352 (7.6%) out of 4,623 treated patients had increased levels of aminotransferase. In 3.2% of patients bosentan therapy must have been withdrawn [6,7]. Dose reduction, withdrawal or discontinuation of the therapy led to return of LFTs levels to pre-treatment values in a few days up to 9 weeks [6,7]. The majority of cases of hepatotoxicity induced by bosentan occurred during the first 26 weeks of treatment (90%), beyond that period probability of this effect was significantly lower [7]. In our opinion the rise of NT-proBNP is secondary to changes in bosentan

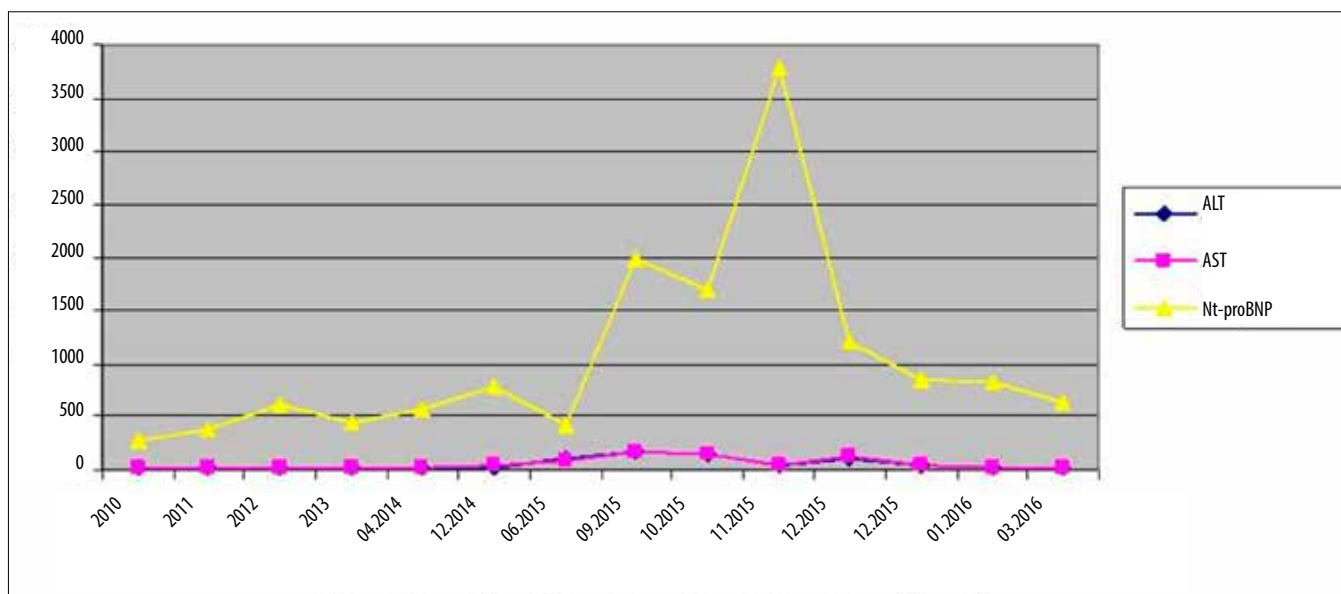


Figure 3. Serial results of blood tests performed during the treatment. ALT – alanine transaminase; AST – aspartate transaminase; NTproBNP– N-terminal prohormone of brain natriuretic peptide

tan therapy – dose reduction and temporary drug withdrawal. Hepatotoxicity occurred during clinically stable period. We did not observe any massive fluid retention or increase of hepatic congestion. It is difficult to unequivocally separate a congestive liver failure from drug related hepatotoxicity. The majority of patients with heart failure and associated liver disease have at least one manifestation. The most common (90–95%) is hepatomegaly due to hepatic congestion. The other symptoms are right upper quadrant pain, cardiac ascites (from few percent up to 25%), splenomegaly (7–20%). The transaminases levels are elevated but usually no more than 2 or 3 times the normal limit. Drug-induced liver injury could take different clinical forms: from asymptomatic elevation of LFTs and bilirubin to acute liver failure with coagulation disorders and encephalopathy. The most convincing in our case was the relationship between drug discontinuation and reduction of signs of liver injury. Our patient did not have any signs of heart failure decompensation or hepatic congestion. Shortly after bosentan withdrawal LFTs and bilirubin level normalized. When we reinitiated the therapy they again began to increase. That convinced us to recognize toxic liver injury.

We present a unique case of drug-induced hepatotoxicity associated with bosentan therapy which occurred after many years of well-tolerated treatment. Moreover, this is probably the first report which confirms successful switching of the bosentan treatment to macitentan in order to reduce elevated liver transaminase levels. An earlier case described a patient with portopulmonary hypertension, who after 18 months developed a severe hepatic injury due to bosentan and also achieved normal transaminase levels after conversion from bosentan to ambrisentan [8]. Macitentan, a novel dual endothelin-receptor antagonist is characterized by sustained receptor binding and enhanced tissue penetration. The SERAFIN study showed that treatment with macitentan reduces morbidity and mortality among patients with PAH [9]. The increase in aminotransferase levels more than 3 times the upper limit of normal was similar in patients treated with macitentan 3 mg QD, macitentan

5 mg QD or placebo [9]. Additionally, MUSIC trial, where patients with idiopathic pulmonary fibrosis were treated with macitentan has also shown that aminotransferase elevations (over 3 times the upper limit of normal) were rare (3.4% in group of macitentan and 5.1% of placebo) [10]. In conclusion, we herein report a successful treatment of liver toxicity due to first generation endothelin receptor antagonist which resolved with improved therapeutic result after a switch to dual specific therapy based on macitentan and sildenafil, in a female with Eisenmenger's syndrome.

References

- Galiè N, Humbert M, Vachiery JL, et al. 2015 ESC/ERS guidelines for the diagnosis and treatment of pulmonary hypertension. *Eur Heart J* 2016; 37: 67–119.
- Lee YH, Song GG. Meta-analysis of randomized controlled trials of bosentan for treatment of pulmonary arterial hypertension. *Korean J Intern Med* 2013; 28(6): 701–707.
- McLaughlin VV, Sitbon O, Badesch DB, et al. Survival with first-line bosentan in patients with primary pulmonary hypertension. *Eur Respir J* 2005; 25: 244–249.
- Galiè N, Beghetti M, Gatzoulis MA, et al. Bosentan therapy in patients with Eisenmenger syndrome: a multicenter, double-blind, randomized, placebo-controlled study. *Circulation* 2006; 114: 48–54.
- Galiè N, Rubin LJ, Hoeper M, et al. Treatment of patients with mildly symptomatic pulmonary arterial hypertension with bosentan (EARLY study): a double-blind, randomized controlled trial. *Lancet* 2008; 371: 2093–2100.
- Humbert M, Segal ES, Kiely DG, et al. Results of European post-marketing surveillance of bosentan in pulmonary hypertension. *Eur Respir J* 2007; 30: 338–344.
- McLaughlin VV, Sitbon O, Badesch DB, et al. Survival with first-line bosentan in patients with primary pulmonary hypertension. *Eur Respir J* 2005; 25: 244–249.
- Eriksson C, Gustavsson A, Kronvall T, et al. Hepatotoxicity by Bosentan in a Patient with Portopulmonary Hypertension: a Case-Report and Review of the Literature. *Med Clin* 2014; 142 (8): 333–342.
- Pulido T, Adzerikho I, Channick RN. Macitentan and morbidity and mortality in pulmonary arterial hypertension. *N Engl J Med* 2013; 369: 809–818.
- Raghu G, Million-Rousseau R, Morganti A, et al. Macitentan for the treatment of idiopathic pulmonary fibrosis: the randomised controlled MUSIC trial. *Eur Respir J* 2013; 42: 1622–1632.