

Wunderlich's syndrome associated with anticoagulant treatment, heart failure, and post-radiation vasculopathy (RCD code: I-O)

Pytlewski Adam¹, Siwek Mateusz¹, Leszek Drabik^{2,3*}, Delikat Miłosz¹, Śmietana Dawid¹, Ewa Sobieraj², Paweł Iwaszczuk², Adam Mazurek², Wojciech Płazak²

¹ Jagiellonian University Medical College, Krakow, Poland; ² Department of Cardiac and Vascular Diseases, John Paul II Hospital, Jagiellonian University Medical College, Krakow, Poland; ³ Department of Pharmacology, Jagiellonian University Medical College, Krakow, Poland

Abstract

Background: Wunderlich's syndrome (WS) is an extremely rare condition, characterised by spontaneous haemorrhage into the subcapsular, perirenal, and retroperitoneal spaces. The most common cause is renal angiomyolipoma. Classic symptoms, such as acute flank pain, flank mass, and hypovolemic shock, known as Lenk's triad, have limited sensitivity and specificity for detecting WS. High mortality may be related to the difficulties in diagnosis, poor disease recognition, and non-specific symptoms and signs. Computed tomography (CT) is the method of choice for the diagnosis of WS. Depending on the severity of symptoms, a conservative or invasive approach is reasonable. **Methods and results:** We report the case of a 58-year-old male with multivalvular heart defect, atrial fibrillation, and exacerbation of chronic heart failure complicated with nontraumatic bleeding into the retroperitoneal space. CT revealed a massive (14x11x26 cm) retroperitoneal and perirenal haematoma. The patient was successfully treated with transfusion of red blood cells, fresh frozen plasma, and intravenous fluids. Simultaneously, heart failure treatment was initiated. In view of the chronic and idiopathic character of the haematoma and successful conservative treatment, there was no indication for surgery. **Discussion:** Several factors might have contributed to the bleeding. First, the patient was receiving anticoagulant treatment to reduce the risk of arterial thromboembolism in atrial fibrillation. Another possible cause is post-radiation vasculopathy, an adverse effect of previous radiation therapy for malignant granuloma. The third factor which could have contributed to bleeding was the exacerbation of chronic heart failure and pulmonary hypertension. JRC D 2019; 4 (2): 55–59

Key words: rare disease, valvular disease, atrial fibrillation, retroperitoneal bleeding, spontaneous haemorrhage, anticoagulation, echocardiography, computed tomography

Background

Definition: Wunderlich syndrome (WS) is defined as spontaneous, nontraumatic haemorrhage into the renal subcapsular, and retroperitoneal spaces. It was described first by Carl Reinhold August Wunderlich in 1858 in "Grundriss der speciellen Pathologie und Therapie"[1].

Epidemiology: Rare disease, a total of 267 cases were reported from 1985 to 2016 [2], including 102 cases described since 2000 [3].

Aetiology and pathogenesis: Causes of WS can be divided into neoplastic, which are more frequent, and non-neoplastic [2].

Neoplastic causes:

1. Renal angiomyolipoma (AML) – a benign tumour of the kidney, is the most common cause of WS, found in 57–73% of cases of WS [4,5]. Frequency of AML in the general population is estimated to be between 0.2% and 0.6%, with a higher prevalence among women. In 20% of cases, AML coexists with tuberous sclerosis complex or pulmonary lymphangiomyomatosis. Usually, AML is an asymptomatic, incidental finding [6].
2. Malignant primary renal tumours e.g. renal cell carcinoma [2].
3. Metastases of malignant tumours to the kidney e.g. choriocarcinoma, gastric sarcoma [7].

Other causes:

Please cite this article: Pytlewski A, Siwek M, Drabik L et al. Wunderlich's syndrome associated with anticoagulant treatment, heart failure and post-radiation vasculopathy (RCD code: I-O). J Rare Cardiovasc Dis. 2019; 4 (2): 55–59; doi: <https://doi.org/10.2041/jrcd.vol4no2.370>

Conflict of interest: none declared. Submitted: April 21, 2019. Accepted: June 17, 2019.

* Corresponding author: Department of Cardiac and Vascular Diseases, Institute of Cardiology, Jagiellonian University Medical College, John Paul II Hospital, Krakow, ul. Pradnicka 80, 31-202 Krakow, Poland; tel: +48 12 614 22 87, fax: 0048 12 423 43 76; e-mail: leszek.drabik@uj.edu.pl

Copyright © 2019 Journal of Rare Cardiovascular Diseases; Fundacja Dla Serca w Krakowie

Learning points:

- Wunderlich syndrome (WS) is rare, spontaneous, nontraumatic bleeding into the sub-capsular, perirenal, and retroperitoneal spaces.
- The most common cause is renal angiomyolipoma.
- Symptoms include acute flank pain, abdominal pain, haematuria, and hypovolemic shock.
- Computed tomography of the abdomen and pelvis is regarded as the gold standard for diagnosis of WS.
- There is no evidence from randomised clinical trials for optimal management of patients with WS. Specialist consultation may be helpful.
- Treatment options are based on aetiology and severity of the bleeding and include blood and fluid resuscitation, endovascular embolization, and partial or total nephrectomy.

1. Vasculopathies: vasculitis (with polyarteritis nodosa being the most common among them), renal artery aneurysms, arteriovenous malformations and fistulas, renal vein thrombosis, or ruptured iliac vein secondary to deep venous thrombosis [2,8].
2. Kidney diseases such as: nephritis, calculus disease, cystic renal diseases [2].
3. Anticoagulant or antiplatelet drugs [9,10].

Clinical picture: The most common signs and symptoms are abdominal pain (67%), haematuria (40%), and shock (26.5%). WS is classically characterised by Lenk's triad: an acute flank pain, flank mass, and hypovolemic shock [1,5]. WS may coexist with hypertension (33–50%) and atherosclerosis (80–87%) [5].

Diagnosis: WS may be missed due to non-specific symptoms and difficulties in diagnosis. Diagnostic procedures focus on identifying the underlying cause of bleeding from unknown sources. A contrast-enhanced abdominal CT is the gold standard for establishing the diagnosis and helpful in evaluation of WS aetiology [7,11].

Treatment: Conservative management including fluid and blood transfusion may be successful in many patients, although in cases of massive bleeding or persistent haemodynamic instability, endovascular embolization or partial/total nephrectomy may be required [5,11].

Case presentation

We present the case of a 58-year-old male with nontraumatic haemorrhage into the retroperitoneal space. Detailed patient's history is described in Table 1.

On admission, the patient's condition was severe with clinical features of biventricular heart failure and acute kidney failure. The patient complained of resting dyspnoea, low urine output, and body mass increase lasting for 2 days. The patient also reported acute pain in the lumbar spine radiating to the right groin. Physical examination revealed signs of pulmonary and systemic congestion and bruising associated with the use of subcutaneous LMWH. BP was 80 mmHg, HR 95 bpm.

Laboratory tests revealed severe hyperkalaemia (6.9 mmol/L), severely impaired kidney function: creatinine 430 μ mol/L, urea 25.6 mmol/L, glomerular filtration rate (estimated glomerular filtration rate [eGFR], 12 ml/min); moderate normocytic anaemia (haemoglobin 8.1 g/dL), significantly elevated natriuretic peptide (N-Terminal Pro-B-Type Natriuretic Peptide [NT-proBNP], 11 567 pg/mL) and C-reactive protein (64 mg/L). TTE showed maintained LVEF, severe multivalvular (aortic, mitral and tricuspid) disease and signs of severe PH (Table 1).

Treatment of acute kidney and heart failure was instituted. The patient had been given dopamine, dobutamine, and loop diuretics. Hyperkalaemia was corrected with intravenous glucose, insulin and polystyrene sulfonate administration. Ceftriaxone was introduced due to urinary tract infection.

In the subsequent days, a decrease in haemoglobin was observed, with the lowest value reaching 7.2 g/dL (Figure 1). Due to inability to localise the source of bleeding, contrast-enhanced CT of the abdomen and pelvis was performed. CT revealed retroperitoneal perirenal haematoma, partially localised in the right iliacus and psoas major muscles originating from the kidney parenchyma. Dimensions of the haematoma were 14x11x26 cm (Figure 2). Urgent consultation with a vascular surgeon was obtained. In view of the chronic and idiopathic character of the haematoma, and hae-

Timeline

Day	Events
1	Anticoagulant therapy with low-molecular-weight heparin (LMWH), bridging therapy before planned heart catheterization was instituted to prevent atrial fibrillation (AF)-related thromboembolism. The patient was in New York Heart Association (NYHA) class II and discharged from the hospital upon his own request.
15	Exacerbation of renal and heart failure (oliguria, weight gain, hypotension). The patient reported severe pain in the lumbar region radiating to right groin. Transthoracic echocardiogram (TTE) revealed severe mitral (MR) and tricuspid regurgitation (TR), low flow low gradient aortic stenosis, and maintained left ventricular ejection fraction (LVEF). Dopamine, dobutamine, and loop diuretics were administered. Hyperkalaemia treated with insulin, fluid therapy, and polystyrene sulfonate. Ceftriaxone was administered for urinary tract infection.
19	Computed tomography (CT) of abdomen and pelvis performed due to progressive anaemia. Large retroperitoneal and perirenal haematoma found. The definitive source of bleeding was unknown. Vascular surgical consultation – recommendation of conservative treatment. Transfusion of red blood cells, fresh frozen plasma, and intravenous fluids. Anticoagulation stopped.
19–22	Clinical improvement was observed. Doses of pressor amines and diuretics gradually reduced. Normalisation of kidney function. Anticoagulation gradually restored.
25	Gastroscopy with duodenoscopy did not reveal a visible source of bleeding.
31	Reduction of MR and TR (moderate/severe) and pulmonary hypertension (PH) in TTE. Patient discharged from hospital in NYHA class II. Heart catheterization delayed for 3 months.

Table 1. Patient's medical history

Disease	Comment	Treatment before hospitalization
Heart failure with preserved ejection fraction	NYHA class IV TTE: maintained left ventricular ejection fraction (LVEF of 50%)	enoxaparin 160 mg/d bisoprolol 5 mg/d torsemide 100 mg/d
Multivalvular heart disease: low flow low gradient aortic stenosis, severe mitral and tricuspid regurgitation	mitral valve regurgitation: vena contracta width (VCW) 7 mm, effective regurgitant area 0.45 cm ² , regurgitant volume 80 ml tricuspid valve: vena contracta width 9 mm aortic valve area 0.9 cm ² , gradient 33/18 mmHg, cusps heavily calcified high probability of pulmonary hypertension, tricuspid regurgitant velocity 3.9 m/s	spironolactone 25 mg/d atorvastatin 40 mg/d ezetimibe 10 mg/d
Coronary artery disease	since 1993 2011 – myocardial infarction of inferior wall (STEMI) treated with percutaneous angioplasty (PCI) of right coronary artery (RCA) with drug eluting stent (DES) implantation 2012 – PCI of RCA with DES implantation	
Hypertension	ESC/ESH grade 2	
Hypercholesterolemia	managed with statin and ezetimibe	
Persistent AF	high thromboembolic risk in CHA ₂ DS ₂ VASc score (3 points) anticoagulation with low molecular weight heparin instituted two weeks before admission	
Chronic kidney disease	grade 3 (KDIGO scale)	
Obesity	BMI 37.6 kg/m ² , height 1.79 m, weight 121 kg	
Malignant granuloma	Remission, radiotherapy and chemotherapy (1991–1993)	

NYHA – New York Heart Association; TTE – transthoracic echocardiography; ESC/ESH – European Society of Cardiology/European Society of Hypertension; CHA₂DS₂VASc – congestive heart failure, hypertension, age ≥75 years, diabetes mellitus, prior stroke or TIA or thromboembolism; KDIGO – Kidney Disease Improving Global Outcomes; BMI – body mass index

modynamic stability, there were no indications for urgent intervention. Four units of packed red blood cells and two units of fresh frozen plasma were transfused without complications. Anticoagulant treatment was temporarily stopped and the patient was given etamsylate. After transfusion, we observed rapid improvement of kidney function (eGFR 50 ml/min). Haemoglobin was stable in further observations (Figure 2). Due to a positive faecal occult blood test, gastroduodenoscopy was performed, which did not reveal the source of bleeding. Anticoagulant treatment with enoxaparin was slowly restored. On the 12th day of hospitalisation, warfarin was introduced. During the next days, enoxaparin was fully replaced with warfarin.

Simultaneously, heart failure treatment was continued and chronic fluid accumulation responded well to standard diuretic therapy (furosemide, thiazides). Reduction in 17 kg of excess water was achieved, resulting in a clinical (NYHA class II) and biochemical improvement (NT-proBNP 3180 pg/mL). In repeated echocardiographic examination, we observed reduction of MR and TR to moderate/severe and reduction of PH. Due to recent retroperitoneal bleeding, coronary angiography before planned heart valve repair/replacement was postponed for 3 months.

Discussion

Signs and symptoms of WS are often nonspecific, causing difficulties in the diagnosis of this life-threatening condition. Numerous

comorbidities may mask WS, as was the case in our patient. Hypotension, impairment of kidney function and anaemia were initially interpreted as symptoms of chronic heart failure exacerbation. The patient's obesity masked signs of intraabdominal bleeding. A decrease in haemoglobin level and resistance to standard therapy for heart failure resulted in further diagnostic workup, which enabled proper diagnosis of this rare disease.

The main reason for the patient's retroperitoneal bleeding could not be determined. The patient reported no history of trauma and a contrast-enhanced CT scan of the abdomen and pelvis did not reveal AML or any other renal tumours, which are considered to be the most common cause of WS [2,6]. Due to risk of exacerbation of kidney failure and the subacute/chronic character of the haematoma, we did not perform CT angiography. Anticoagulant treatment, which was instituted 2 weeks before bleeding, is the first and most probable cause of the bleeding. Mao Y et al. reported anticoagulation as the cause of 27.1% of perirenal haemorrhages [12]. WS was associated with the use of warfarin (41.6%), unfractionated heparin (30.3%), LMWH (11.2%), antiplatelet therapy (30.3%), or combined treatment (16.5%) [13,14]. Triscott et al. described 36 reported cases of spontaneous retroperitoneal haemorrhage (SRH) and WS associated with the use of enoxaparin. The bleeding was fatal in 33% of the cases. Risk factors for bleeding included an older age, renal insufficiency, treatment with non-steroidal inflammatory drugs, antiplatelet drugs, or anticoagulants [14,15]. In our PubMed search, as of 2010, there were 31 cases of WS associated with the use of antiplatelets or anticoagulants including heparin (45.1%), war-

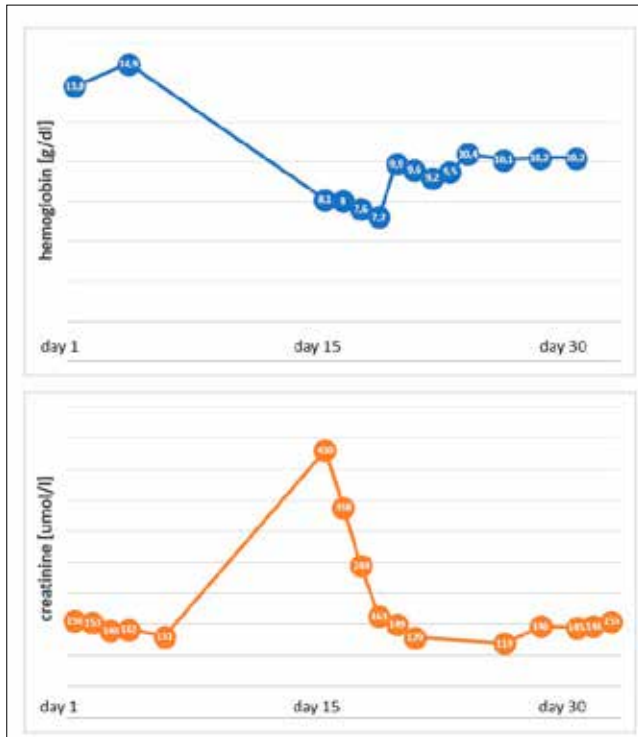


Figure 1. Level of hemoglobin and creatinine before and during hospitalization

farin (29.1%), acetylsalicylic acid (16.1%), and clopidogrel (9.7%), which is in line with previous observations [14]. There is limited data on the safety and efficacy of new antiplatelets or anticoagulants in WS. In the Platelet Inhibition and Patient Outcomes (PLATO) trial, ticagrelor increased the risk of retroperitoneal haematoma or haemorrhage by 49% when compared to clopidogrel [16]. In the EINSTEIN-DVT and EINSTEIN-PE trials evaluating the use of rivaroxaban vs LMWH/warfarin therapy for the treatment of ve-

nous thromboembolism, a significantly lower rate of major bleeding, including retroperitoneal bleeding in patients was observed in the group treated with rivaroxaban [17]. Retroperitoneal haematomas in patients with coagulation abnormalities and vascular diseases were larger and more likely to extend into the perirenal space [12]. Hereditary blood-clotting disorders cannot be excluded in our patient, however, thrombophilia testing was unavailable at that time. Another potential cause was the previous radiotherapy for treatment of malignant granuloma. Vasculopathy is a potential complication of radiation therapy, which can increase the risk of vessel rupture and bleeding [18]. WS occurred more than 10 years after completing radiotherapy, which makes definitive causality difficult to establish but it cannot be excluded. Advanced heart failure and severe pulmonary hypertension might have contributed to SRH and WS [19,20].

There is no general consensus as to the best management plan for patients with WS. In this particular case, conservative management was successful. Most haemodynamically stable patients can be managed with fluid resuscitation, correction of coagulopathy, and blood transfusion. Endovascular treatment involving selective intra-arterial embolization or the deployment of stent-grafts over the ruptured vessel is attaining an increasingly important role. Open repair should be reserved for cases when there is failure of conservative or endovascular measures to control the bleeding or endovascular facilities are unavailable [7,21]. Open repair of retroperitoneal bleeding vessels should be reserved for cases when there is failure of conservative or endovascular measures to control the bleeding. Open repair is also required if endovascular facilities or expertise is unavailable and in cases where the patient is unstable. Despite available treatment options, the mortality of patients with retroperitoneal haematoma remains high.

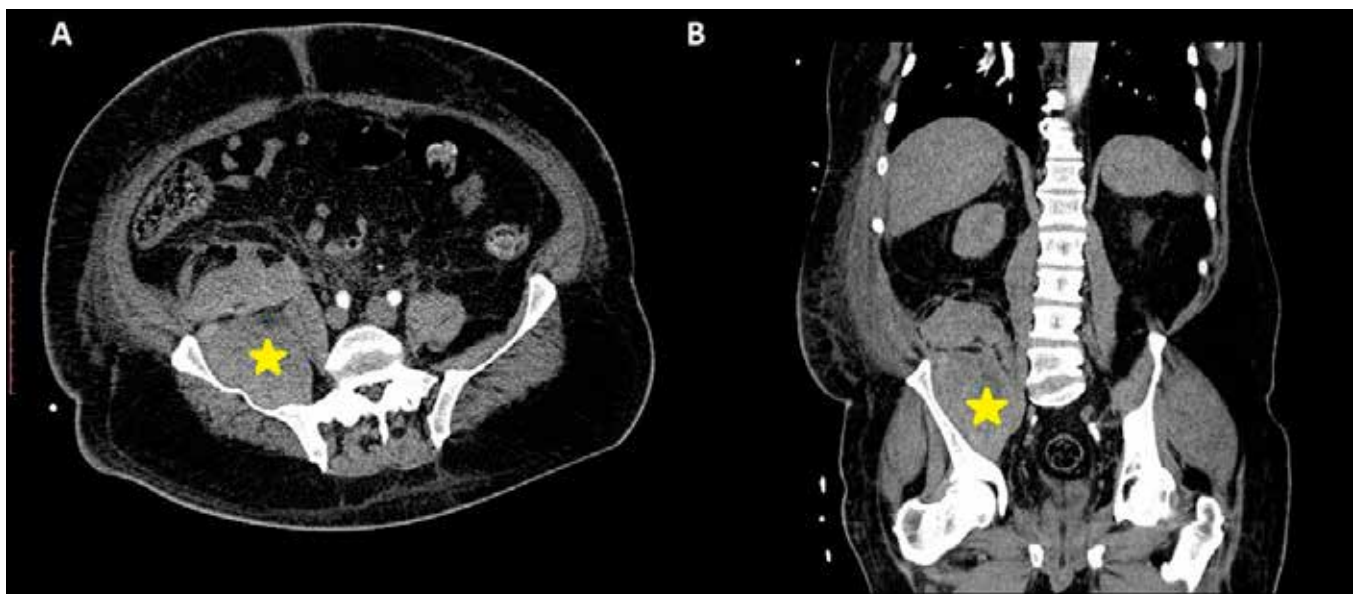

Figure 2. A CT scan of the abdomen and pelvis (transverse section [A], coronal section [B]); showing retroperitoneal haematoma, marked with a yellow star

References

1. Wunderlich C. *Handbuch der Pathologie und Therapie*. 2nd ed. St. 1856.
2. Zhang JQ, Fielding JR, Zou KH. Etiology of spontaneous perirenal hemorrhage: a meta-analysis. *J Urol* 2002;167:1593–6.
3. Ahn T, Roberts MJ, Navaratnam A, et al. Changing etiology and management patterns for spontaneous renal hemorrhage: a systematic review of contemporary series. *Int Urol Nephrol* 2017;49:1897–905. doi:10.1007/s11255-017-1694-8
4. Vos N, Oyen R. Renal Angiomyolipoma: The Good, the Bad, and the Ugly. *J Belgian Soc Radiol* 2018;102:41. doi:10.5334/jbsr.1536
5. Daliakopoulos SI. Spontaneous retroperitoneal hematoma: a rare devastating clinical entity of a pleiada of less common origins. *J Surg Tech Case Rep* 2011;3:8–9. doi:10.4103/2006–8808.78462
6. Flum AS, Hamoui N, Said MA, et al. Update on the Diagnosis and Management of Renal Angiomyolipoma. *J Urol* 2016;195:834–46. doi:10.1016/j.juro.2015.07.126
7. Sierra-Díaz E, Belmonte-Hernández MV, Villanueva-Pérez MA, et al. Non-traumatic spontaneous retroperitoneal bleeding: the effect of an early and accurate diagnosis. *Cir Cir* 2015;83:206–10. doi:10.1016/j.circir.2015.05.014
8. González-Castro A, Ortiz-Lasa M, García-Reyero J, et al. Wunderlich syndrome due to a ruptured iliac vein secondary to deep venous thrombosis. *Rev Española Patol* 2018;51:197–202. doi:10.1016/j.patol.2017.07.001
9. Yamamoto K, Yasunaga Y. Antiplatelet therapy and spontaneous perirenal hematoma. *Int J Urol* 2005;12:398–400. doi:10.1111/j.1442–2042.2005.01059.x
10. Akuzawa N, Kurabayashi M. Multiple spontaneous hemorrhages after commencing warfarin therapy. *SAGE open Med case reports* 2018;6:2050313X18778380. doi:10.1177/2050313X18778380
11. Wang BH, Pureza V, Wang H. Editor's choice: A tale of Wunderlich syndrome. *J Surg Case Reports* 2012;2012:rjs015. doi:10.1093/JSCR/RJS015
12. Mao Y, De Oliveira IS, Hedgire S, et al. Aetiology, imaging features, and evolution of spontaneous perirenal haemorrhage. *Clin Radiol* 2017;72:175.e19–175.e26. doi:10.1016/j.crad.2016.08.010
13. Drabik L, Wołkow P, Undas A. Denser plasma clot formation and impaired fibrinolysis in paroxysmal and persistent atrial fibrillation while on sinus rhythm: Association with thrombin generation, endothelial injury and platelet activation. *Thromb Res* 2015;136:408–14. doi:10.1016/j.thromres.2015.05.028
14. Triscott J, Mercer S, Tian PGJ, et al. Retroperitoneal haematoma associated with enoxaparin use in an elderly woman with chronic kidney disease. *BMJ Case Rep* 2015;2015:bcr2015211699. doi:10.1136/bcr-2015-211699
15. Drabik L, Wołkow P, Undas A. Fibrin Clot Permeability as a Predictor of Stroke and Bleeding in Anticoagulated Patients With Atrial Fibrillation. *Stroke* 2017;48:2716–22. doi:10.1161/STROKEAHA.117.018143
16. DiNicolantonio JJ, D'Ascenzo F, Tomek A, et al. Clopidogrel is safer than ticagrelor in regard to bleeds: a closer look at the PLATO trial. *Int J Cardiol* 2013;168:1739–44. doi:10.1016/j.ijcard.2013.06.135
17. Health V, Management R. *Vascular Health and Risk Management Dovepress* Evaluation of bleeding in patients receiving direct oral anticoagulants. 2017;13–325. doi:10.2147/VHRM.S121661
18. Weintraub NL, Jones WK, Manka D. Understanding radiation-induced vascular disease. *J Am Coll Cardiol* 2010;55:1237–9. doi:10.1016/j.jacc.2009.11.053
19. Drabik L, Kopeć G, Podolec P. Rapid progressive idiopathic pulmonary arterial hypertension (ICD code: I11.1). *J Rare Cardiovasc Dis* 2013;1:33–8. doi:http://dx.doi.org/10.20418%2Fjrvc.vol1no2.80
20. Rubiś P, Drabik L, Kopeć G, et al. The prognostic role of exercise echocardiography in heart failure. *Kardiol Pol* 2011;69:656–63.
21. Chan YC, Morales JP, Reidy JF, et al. Management of spontaneous and iatrogenic retroperitoneal haemorrhage: conservative management, endovascular intervention or open surgery? *Int J Clin Pract* 2007;62:1604–13. doi:10.1111/j.1742–1241.2007.01494.x
22. Sunga KL, Bellolio MF, Gilmore RM, et al. Spontaneous Retroperitoneal Hematoma: Etiology, Characteristics, Management, and Outcome. *J Emerg Med* 2012;43:e157–61. doi:10.1016/j.jemermed.2011.06.006